

JAMA Dermatology

Formerly *Archives of Dermatology*

Reprint Article

Original Investigation

Use of a Picosecond Pulse Duration Laser With Specialized Optic for Treatment of Facial Acne Scarring

Jeremy A. Brauer, MD; Viktoryia Kazlouskaya, MD, PhD; Hamad Alabdulrazzaq, MBBCh; Yoon Soo Bae, MD; Leonard J. Bernstein, MD; Robert Anolik, MD; Patricia A. Heller, MD; Roy G. Geronemus, MD

Reprinted Article from: PUBLISHED ONLINE doi:10.1001/jamadermatol.2014.3045 | Pages E1 - E7 | November 19, 2014



A JAMA NETWORK
PUBLICATION

Original Investigation

Use of a Picosecond Pulse Duration Laser With Specialized Optic for Treatment of Facial Acne Scarring

Jeremy A. Brauer, MD; Viktoryia Kazlouskaya, MD, PhD; Hamad Alabdulrazzaq, MBBCh; Yoon Soo Bae, MD; Leonard J. Bernstein, MD; Robert Anolik, MD; Patricia A. Heller, MD; Roy G. Geronemus, MD

+ Supplemental content at
jamadermatology.com

IMPORTANCE Fractional laser technology is routinely used in the treatment of acne scarring, with thermal injury resulting in collagen synthesis and remodeling. Use of a picosecond pulse duration with a diffractive lens array may be a new technologic advancement in the treatment of acne scarring.

OBJECTIVE To investigate the safety and efficacy of a 755-nm alexandrite picosecond pulse duration laser with diffractive lens array for the treatment of facial acne scarring.

DESIGN, SETTING, AND PARTICIPANTS This single-center, prospective study performed in a private practice with a dedicated research department included patients with clinically diagnosed scarring secondary to inflammatory or cystic acne.

INTERVENTIONS Patients received 6 treatments with a 755-nm picosecond laser with a spot size of 6 mm, fluence of 0.71 J/cm², repetition rate of 5 Hz, and pulse width of 750 picoseconds in combination with a diffractive lens array, allowing for greater surface area and pattern density per pulse.

MAIN OUTCOMES AND MEASURES The pain and satisfaction scores for overall appearance and texture were recorded. Masked assessment of clinical photographs and analysis of 3-dimensional volumetric data were performed. Biopsy specimens were obtained for independent histologic evaluation by 2 investigators at baseline and at 3 months after last treatment.

RESULTS Fifteen women and 5 men (mean age, 44 years; age range, 27-61 years) with Fitzpatrick skin types I through V and facial acne scarring were enrolled. The mean pain score was 2.83 of 10. Patients were satisfied to extremely satisfied with improvement in appearance and texture at their final treatment and follow-up visits. The masked assessment scores of 17 patients were 1.5 of 3 and 1.4 of 3 at 1 and 3 months, respectively (a score of 0 indicates 0%-25% improvement and a score of 3 indicates >75% improvement). A 3-dimensional analysis revealed a mean 24.3% improvement in scar volume, maintained at 1 (24.0%) and 3 (27.2%) months after treatment. Histologic analysis revealed elongation and increased density of elastic fibers, with an increase in dermal collagen and mucin.

CONCLUSIONS AND RELEVANCE Treatment of facial acne scars with a diffractive lens array and 755-nm picosecond laser produced improvement in appearance and texture at 3 months after the last treatment, with objective findings similar to those published for a series of fractional ablative laser treatments. Histologic findings suggest that improvement in scarring from this treatment goes beyond remodeling of collagen.

Author Affiliations: Laser & Skin Surgery Center of New York, New York, New York (Brauer, Alabdulrazzaq, Bae, Bernstein, Anolik, Geronemus); Ronald O. Perleman Department of Dermatology, NYU Langone Medical Center, New York, New York (Brauer, Anolik, Geronemus); Ackerman Academy Dermatopathology, New York, New York (Kazlouskaya, Heller); Department of Dermatology, Weill Cornell Medical Center, New York, New York (Bernstein, Anolik).

Corresponding Author: Jeremy A. Brauer, MD, Laser & Skin Surgery Center of New York, 317 E 34th St, New York, NY 10016 (jbrauer@laserskinsurgery.com).

JAMA Dermatol. doi:10.1001/jamadermatol.2014.3045 (REPRINTED)
Published online November 19, 2014.

Acne and subsequent scarring affect patients of all ages and ethnicities and can cause severe psychological effects.¹ Acne scars have been categorized as atrophic (icepick, boxcar, or rolling), hypertrophic, and keloid scars.² Historically, acne scarring has been treated by chemical peeling for superficial scars, dermabrasion for deeper scars, subcision to release fibrous tethering below the acne scar (with or without concurrent use of fillers), and punch excisions and elevations to remove deeper scars.³ More recent treatments include the use of a plasma skin regeneration system, autologous fibroblasts, platelet-rich plasma, and needling.³⁻⁸ Lasers, intense pulsed light, and other energy devices are also regularly used in the treatment of scarring and fractional resurfacing, whether with ablative or nonablative devices, and have become the current standard of care.^{3,4} These resurfacing procedures often require anesthesia, sometimes with prolonged healing and greater risk of adverse events, and restrictions on appropriate patient populations.

Many of these modalities are used alone or in combination, each with their own advantages, disadvantages, and contraindications. Multiple retrospective and prospective studies have contributed to our understanding of these devices and approaches to treating acne scars. However, there is room to improve the efficacy and recovery of treating the multiple types of acne scars we encounter, for patients with all skin types, in a safe manner.

The Food and Drug Administration approved the use of a 755-nm picosecond alexandrite laser (Cynosure) for the treatment of unwanted tattoos. The evolution from traditional nanosecond to picosecond lasers has been observed to produce a photomechanical effect that causes fragmentation of tattoo ink or pigment.⁹ This technology can be used to deliver lower fluences of energy, theoretically leading to fewer adverse effects, to affect tattoo pigment particles and melanosomes because these chromophores have a thermal relaxation time of less than 10 nanoseconds.⁹

Furthermore, an innovative optical attachment for the picosecond laser, a diffractive lens array, has been developed that gauges distribution of energy to the treatment area. This specialized optic affects more surface area, has a greater pattern density per pulse, and may improve the appearance of acne scars. We describe the use of a picosecond 755-nm laser with a diffractive lens array in the treatment of facial acne scarring.

Methods

Men and women with Fitzpatrick skin types I through V and facial acne scarring were enrolled. The study received institutional review board approval from the New England Institutional Review Board, and all patients provided written informed consent. Patients had to be otherwise healthy without a history of skin cancer (including melanoma and nonmelanoma skin cancer), keloidal scarring, localized or active infection, immunodeficiency disorders, and light hypersensitivity or taking medications with known phototoxic effects. In addition, they could not have been taking isotretinoin for a pe-

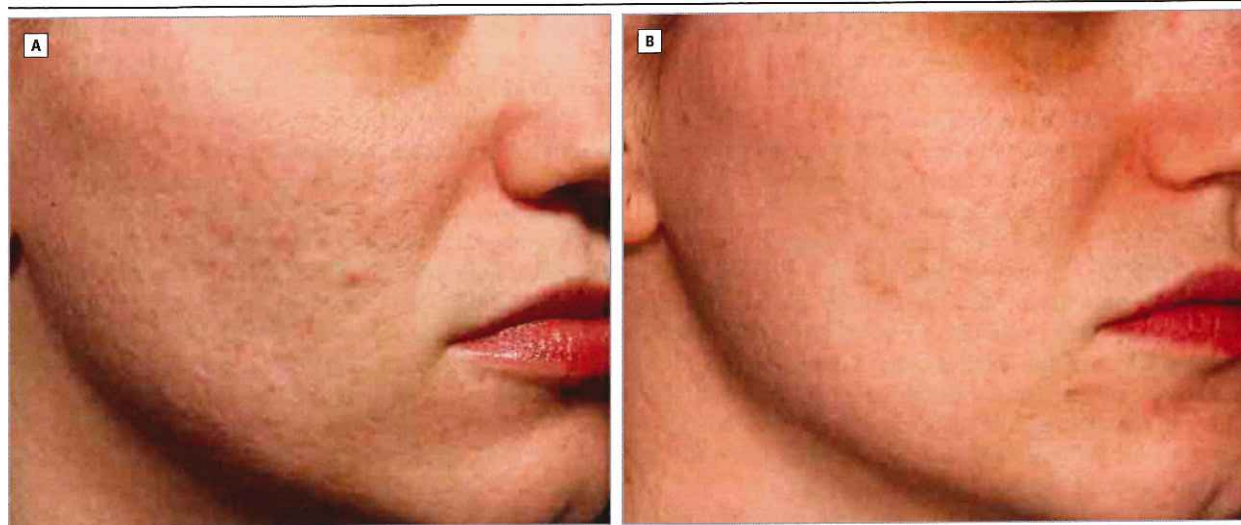riod of 12 months before treatment. Pregnant or breastfeeding women were also excluded. Demographic data were obtained from all enrolled patients, and study investigators assigned skin type (Fitzpatrick skin types I-VI) and qualified the type of acne scarring within the treatment areas.

Facial photography and 3-dimensional imaging (PRIMOS imaging system; Canfield Scientific Inc) to measure scar volume were performed, and 6 treatments with a 755-nm alexandrite picosecond pulse duration laser with a diffractive lens array were performed every 4 to 8 weeks. Treatment intervals were determined based on the Fitzpatrick skin types of the patients. All areas of scarring were treated, and patients had the option to treat the remainder of the face as well. Selected spot size, fluence, frequency, and pulse duration were standardized and used for all patients (spot size, 6 mm; fluence, 0.71 J/cm²; repetition rate, 5 Hz; and pulse width, 750 picoseconds). A diffractive lens array was applied to the handpiece to allow for delivery of varying levels of heat at this fixed spot size and fluence. Specifically, the array is made up of approximately 120 closely packed diffractive lenses that redistribute energy into evenly spaced high-energy pulses, affecting approximately 5% to 10% of the total treatment spot. These high-energy pulses are 20 times the energy of the lower-level heating that surrounds these defined areas (eFigure in the Supplement). Therefore, the number of pulses or passes was the only variable treatment parameter, dependent on skin type and size of treatment area. After treatment, patients were advised to avoid sun exposure and to use a broad-spectrum sunscreen daily on the treated areas. Topical anesthesia with lidocaine, 2.5%, and prilocaine cream, 2.5%, and antiviral prophylaxis with acyclovir were offered to all patients. Anesthesia was applied 1 hour before treatment, and use of acyclovir was continued for 4 days after treatment.

Two patients agreed to and signed written informed consent forms for skin biopsies to be performed in areas of treatment before initiation of and at 3 months after treatment. Administration of local anesthesia was achieved with injection of lidocaine, 2%, with epinephrine, and 2-mm punch biopsies were performed, with 6-0 nylon sutures (Ethicon Inc) used for closure. These patients returned for an additional office visit 7 days later. Specimens were submitted in Michel medium, frozen at -20°C, and washed with phosphate-buffered saline. Specimens were stained with elastic-van Gieson stain (Dako), colloidal iron (Poly Scientific R&D Corp), and collagen I and III antibodies (Sigma-Aldrich Co LLC; dilution 1:200). Immunohistochemical analysis was performed on commercially available, positively charged slides (Thermo Fisher Scientific Inc) and processed on a Benchmark XT Stainer (Ventana Medical Systems Inc). Appropriate controls were studied. Character of elastic fiber and changes in density, distribution of mucopolysaccharide deposition, and collagen were independently evaluated by 2 investigators (V.K. and P.A.H.) using standard microscopic evaluation of tissue at baseline and 3 months after treatment.

Patients were asked to provide a subjective score for pain experienced during each treatment session ranging from 0 (no pain) to 10. Before their final treatment visit and at 1 and 3 months after the sixth treatment visit, patients were asked to

Figure 1. Facial Acne Scarring in a Young Woman



A, Baseline appearance. B, Improvement in appearance and texture of scarring on the cheeks 3 months after 6 full-face treatments.

rate their satisfaction with improvement in overall appearance and texture on a 4-point scale (0 indicating not satisfied; 1, dissatisfied; 2, satisfied; and 3, extremely satisfied).

Three independent masked physician evaluators used a 4-point scale (0 indicating 0%-25%; 1, 26%-50%; 2, 51%-75%; and 3, 76%-100%) to assess improvement at 1 and 3 months after 6 treatment sessions. Improvement in volume, texture, and overall appearance of the treatment areas was assessed with before-and-after photographs. These independent evaluators were masked to the chronologic order of the photographs and were not involved with patient enrollment, device treatments, and study visits.

Results

Twenty patients, 15 women and 5 men, were enrolled, and 17 completed all 6 treatments and presented for 1- and 3-month follow-up visits. Patient ages ranged from 27 to 61 years, with a mean age of 44 years. Individuals with Fitzpatrick skin types I through V were enrolled, with 7 patients (41%) categorized as having Fitzpatrick skin type II, 6 patients (35%) as having type III, 3 patients (18%) as having type IV, and 1 patient (6%) as having type I. On initial physical examination, of the 17 patients, most had rolling-type acne scars (16 [94%]), 4 (24%) had boxcar scars, and 3 (18%) had icepick lesions.

Only 1 of the 17 patients requested application of topical anesthesia before treatment. Treatments were performed every 4 to 8 weeks, with the total number of pulses ranging from 2305 to 4017 (mean, 3073 pulses). The mean pain score was 2.83 of 10 (range, 1-7). The mean pain scores increased with each treatment session from 2.66 at the first session to 3.25 after the sixth session, likely reflecting an increased mean number of pulses. Patients were satisfied to very satisfied with overall appearance and texture at the final treatment session and at 1 and 3 months, with scores on a range of 0 to 3 of 2.33, 2.45, and 2.2

for overall appearance and 2.33, 2.36, and 2.2 for texture. By patient report, immediately after treatment, only transient erythema and edema were experienced, which resolved within hours to at most 2 days.

Masked assessment of 2-dimensional photography of 17 patients was performed, with mean scores of 1.5 and 1.4 at 1 and 3 months, respectively (score range of 0 indicating 0%-25% improvement to 3 indicating >75% improvement). Analysis of 3-dimensional data of 10 of 17 patients yielded a mean 24.3% improvement in scar volume at the sixth treatment session. This benefit was maintained at 1 (24%) and 3 (27%) months after treatment (Figure 1 and Figure 2).

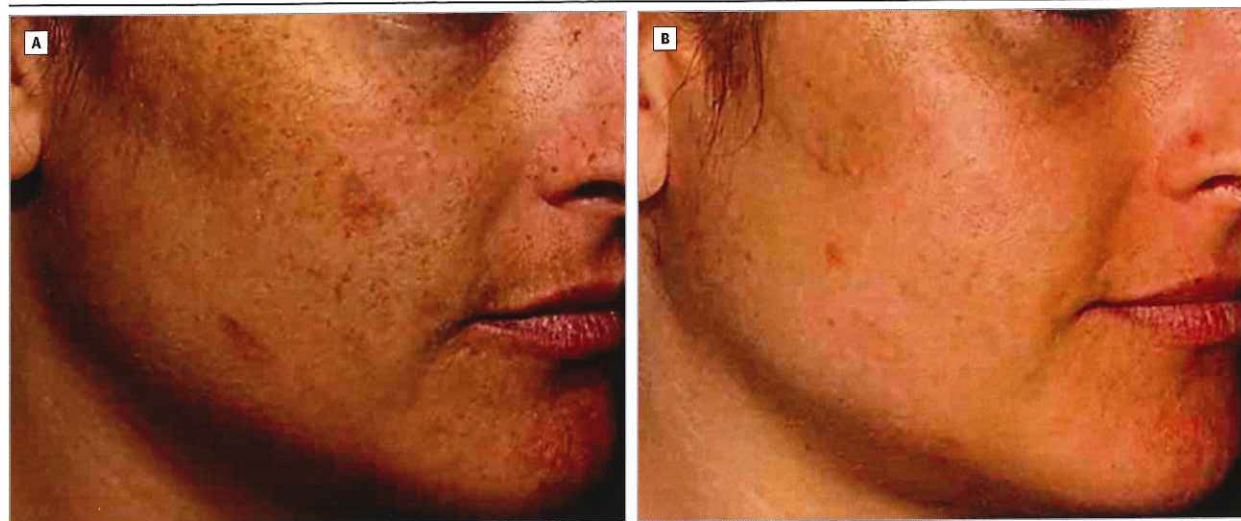Although not initially defined as a study end point, one consistent and unanticipated finding was significant subjective clinical improvement in texture and pigmentation of uninvolved skin. In particular, one patient with a Nevus of Ota and melasma that opted for full-face treatment had pronounced clearing of pigmentation not only in the areas of scarring but also in areas of the Nevus of Ota and melasma (Figure 2).

Evaluation of histologic specimens at 3-month follow-up revealed notable changes from baseline. Specifically, within the dermis there was an elongation and increased density of elastic fibers, an increase in collagen III, and an increase in deposition of mucin throughout all the layers of the dermis (Figures 3, 4, and 5). For collagen I staining, no visible changes between baseline and follow-up were noted because it stained the dermis in its entirety in all specimens.

Discussion

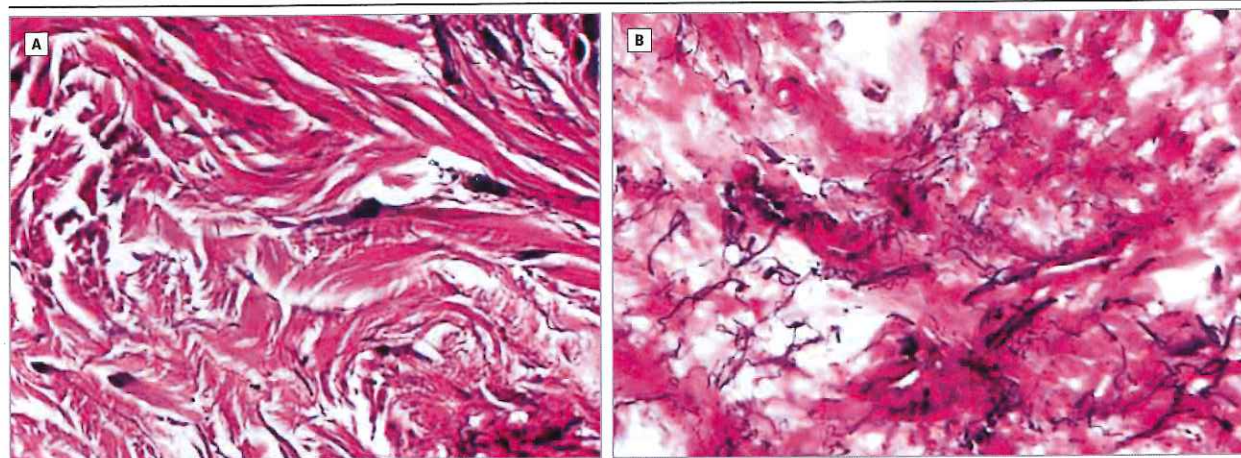
This is the first study, to our knowledge, to report the efficacy of the 755-picosecond laser and diffractive lens array technology in the management of facial acne scarring. Treatments were performed safely in individuals with skin types I through IV,

Figure 2. Acne Scarring, Nevus of Ota, and Melasma in a Young Woman



A, Baseline appearance. B, Improvement in appearance and texture of scarring, Nevus of Ota, and melasma 3 months after 6 full-face treatments.

Figure 3. Histologic Findings in Elastic Fibers

A, Baseline specimen. B, Increase in density and elongation of elastic fibers 3 months after 6 treatments. Elastic-van Gieson stain; original magnification $\times 400$.

requiring minimal preparation and having little downtime. Not only was the treatment well tolerated by patients, with a mean pain score of 2.8 of 10, it also had a favorable safety profile as indicated by a lack of observed adverse effects. Clinical efficacy was maintained at 3 months after treatment using subjective and objective measurements, and histologic analysis revealed increases in collagen and mucin with an increase in density of elastic fibers.

The 755-picosecond laser is highly effective in the rapid clearance of tattoos, especially those with green and blue pigment.^{10,11} For our study, a specialized diffractive lens array was used to alter the distribution of energy delivered to the skin. Standard handpieces deliver the energy in a uniform fashion. In contrast, this particular optic, initially developed to safely treat individuals of darker skin types, delivers variable levels of heat energy at a fixed spot size of 6 mm and energy density of 0.71 J/cm², with 70% delivered as high-energy pulses

that are 500 μ m apart, and the surrounding areas receive low-level heat energy. By using the diffractive lens array, approximately 5% to 10% of the cutaneous surface area receives the higher fluence, whereas the remaining surface is exposed to a background of low-level heat. Although it was previously suggested that a longer pulse duration would result in the desired thermal effect and clinical outcome,¹² we found good efficacy with collagen stimulation and remodeling with a shorter pulse duration.

In this prospective study, treatments were performed only on atrophic facial acne scars, in particular the rolling subtype, which result from tethering or anchoring of the dermis to the subcutaneous layer.² Because of the nature of these scars, it has typically been recommended that mechanical techniques, such as subcision, be performed to obtain good clinical outcomes. More recently, fillers, such as polymethylmethacrylate microspheres in collagen, have shown promise.¹³

Figure 4. Histologic Findings in Dermal Collagen Deposition

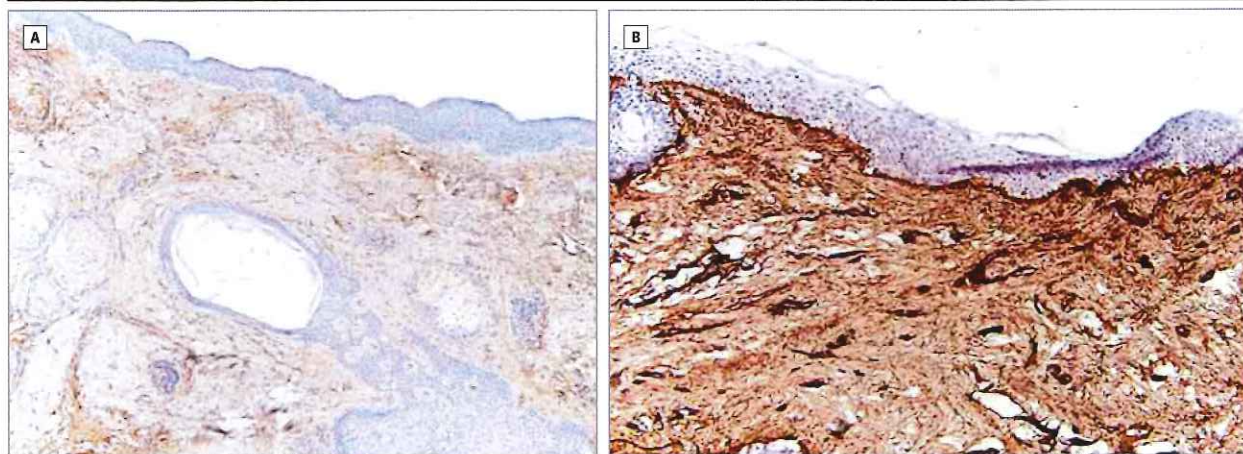
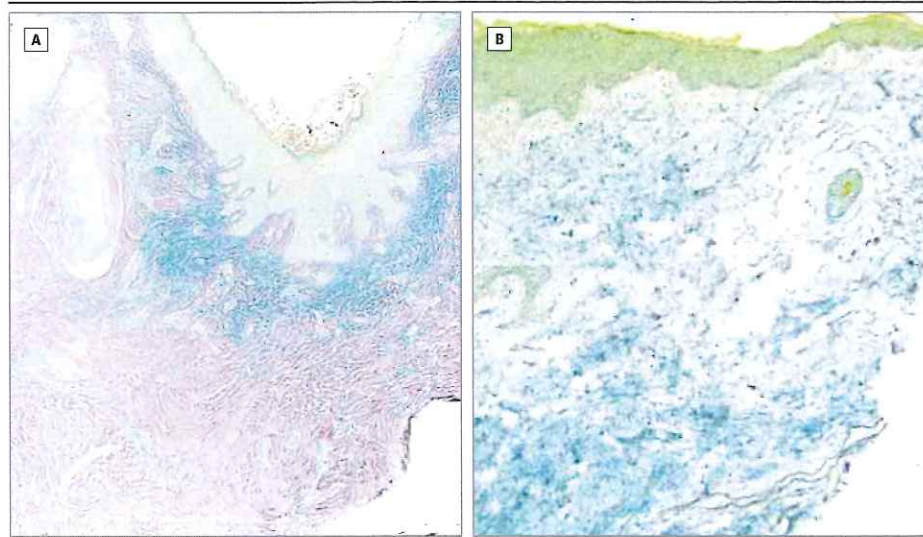
A, Baseline specimen. B, Increase in dermal collagen deposition 3 months after 6 treatments. Collagen III stain; original magnification $\times 100$.

Figure 5. Histologic Findings in Dermal Mucin Deposition

A, Baseline specimen. B, Increase in dermal mucin deposition 3 months after 6 treatments. Colloidal iron stain; original magnification $\times 100$.

Regarding recent advances in the use of lasers, Sardana et al¹⁴ found a 43% improvement of depth to width ratio using a 1540-nm fractional nonablative laser; for their study, greater than 51% improvement was considered meaningful. Other options include the use of a microsecond Nd:YAG laser and ablative fractional devices.¹⁵ Our findings indicate that the picosecond laser can be added as another safe treatment option.

Although several different grading systems have been proposed¹⁶⁻¹⁸ to standardize acne scar classification and evaluation, there is no accepted criterion standard scale. Similarly, there is no widely accepted device for measuring acne scar improvement in a reproducible and objective fashion. The lack of a standardized acne scar measurement scale has led to great variability in evaluation and interpretation of data in different studies. To demonstrate efficacy, we used masked clinical assessments, patient improvement evaluations, objective measurements with the PRIMOS imaging system, and histologic analyses.

Our masked assessments of 2-dimensional photographs performed by 3 dermatologists (Y.S.B., L.J.B., and R.A.) found a 25% to 50% global improvement at the 1-month follow-up, which was maintained at the 3-month visit. To supplement the improvement scales, objective measurements of improvement were used, including the PRIMOS imaging system and histologic assessment. The PRIMOS imaging system obtains in vivo 3-dimensional images of the skin's microtopography,¹⁹ allowing for assessment of scar depth and volume and for measurement of improvement over time. Our results indicate a mean improvement in scar volume of 24.3% after treatment completion. Improvement was maintained at the 1- and 3-month follow-ups, with a mean of 24.0% and 27.2%, respectively. One limitation, however, was the potential for lack of reproducibility with possible variation in angle or pressure, as well as misalignment of before-and-after images.

These objective findings correlated well with the clinical improvement scales and compare favorably with data in the

existing literature. A mean improvement of 38.0% in scar volume was achieved after 3 treatments with an ablative fractional device, performed at 1- to 4-month intervals, in one study²⁰ that examined atrophic postoperative and traumatic scarring. Compared with treatments performed in this study, ablative fractional resurfacing procedures require far more preparatory effort, including nerve blocks and a course of oral corticosteroids, with a prolonged period of recovery.

Biopsy specimens taken from 2 patients at baseline and at the 3-month follow-up revealed increased density and elongation of the elastin fibers in the dermis. Collagen III and mucin deposition were also increased. The increase in collagen III reflects the effects of the treatment in dermal wound healing and neocollagenesis.²¹ Significant increases in dermal elastin fibers have also been found using a 1540-nm fractional laser,²² suggesting that elastogenesis and possibly other mechanisms play a role in the improvements seen. Interaction of picosecond duration laser radiation with tissue involves photothermal and photomechanical processes; however, given the low fluence used in this study, it is more likely that the efficacy arises in large part from the latter.

We believe increasing the number of pulses used in each treatment session could have resulted in a better clinical outcome. Initial treatments were conservative to assess for tolerability and adverse reactions. In general, as the safety profile declared itself and patients demonstrated tolerance, the mean number of pulses when full-face treatments were performed was generally increased.

Even with this increase in number of pulses, patients were satisfied to very satisfied and tolerated the treatments well. Little preparation was required, with the face cleansed to remove any makeup or excess sebum before initiating treatment. All but one of the patients did not require any topical anesthesia, and no analgesia cooling technologies were used during the treatment sessions. The mean pain score was mild, gradually increasing from 2.66 in the first treatment to 3.25 after the sixth treatment. This slight increase likely correlated with the increase in number of pulses per session during the study period. Downtime was

minimal, with patients experiencing transient facial erythema and mild edema, and no exfoliation, vesiculation, crusting, scarring, hypopigmentation, or postinflammatory pigment alteration noted. Most important, unlike existing laser resurfacing modalities, this favorable safety profile was reproducible across all skin types treated, including Fitzpatrick skin types I through V.

Our study was limited by a follow-up period of only 3 months, relatively small sample size, and lack of a control (split-face design) or comparative group. In addition, although photographs were not evaluated in chronologic order, because the 755-nm wavelength is absorbed by pigment, evaluators may be able to determine order by improvement in facial dyspigmentation. Because this was a pilot study, there was a period of acquisition as treatment parameters were established, specifically the treatment intervals and number of pulses, which were maintained on the conservative side during the earlier sessions. Because of the difficulty of recruiting patients for facial skin biopsies, the histologic analysis was limited to 2 patients. Findings were demonstrated and consistent in both samples, and the use of immunostaining does not allow for quantifying changes or reveal smaller changes, which likely explains why no changes were noted in collagen I staining. Finally, with the lack of a proper streamlined scale to assess acne scar improvement, 3-dimensional imaging was used to add objective support to the clinical evaluations; however, difficulty remains in obtaining precise measurements.

Conclusions

In summary, this is the first study, to our knowledge, that demonstrates favorable clinical outcomes in acne scar management with the 755-picosecond laser and diffractive lens array. Observed improvement in pigmentation and texture of the surrounding skin suggests that there may be benefits for indications beyond scarring. Additional studies with larger sample sizes, specific scar subtype stratification, and histologic analyses are needed.

ARTICLE INFORMATION

Accepted for Publication: August 12, 2014.

Published Online: November 19, 2014.
doi:10.1001/jamadermatol.2014.3045.

Author Contributions: Drs Brauer and Geronemus had full access to all the data in the study and take responsibility for the integrity of the data and the accuracy of the data analysis.

Study concept and design: Brauer, Heller, Bae, Anolik, Geronemus.

Acquisition, analysis, or interpretation of data: All authors.

Drafting of the manuscript: Brauer, Kazlouskaya, Alabdulrazzaq, Bae, Heller, Geronemus.

Critical revision of the manuscript for important intellectual content: Brauer, Bae, Bernstein, Anolik, Heller.

Statistical analysis: Brauer, Kazlouskaya, Alabdulrazzaq.

Obtained funding: Geronemus.

Administrative, technical, or material support:

Brauer, Bae, Bernstein, Anolik, Heller, Geronemus.
Study supervision: Geronemus.

Conflict of Interest Disclosures: Dr Brauer reported receiving honoraria from Cynosure/Palomar Medical Technologies Inc and performing consultancy work for Miramar. Dr Geronemus reported receiving honoraria from Cynosure/Palomar Medical Technologies Inc, owning stocks or having stock options with Zeltiq Aesthetics Inc and OnLight Sciences, and serving on the medical advisory board of Zeltiq Aesthetics Inc, Syneron Inc and Candela Corporation, and Cynosure/Palomar Medical Technologies Inc. No other disclosures were reported.

Funding/Support: This study was supported in part by Cynosure.

Role of the Sponsor: Cynosure had a role in the design of the study but not the conduct, collection, management, analysis, or interpretation of data. They approved the manuscript but did not prepare or decide to submit.

Additional Contributions: We are indebted to the Research Department at the Laser & Skin Surgery Center of New York.

REFERENCES

1. Fried RG, Wechsler A. Psychological problems in the acne patient. *Dermatol Ther*. 2006;19(4):237-240.
2. Jacob CI, Dover JS, Kaminer MS. Acne scarring: a classification system and review of treatment options. *J Am Acad Dermatol*. 2001;45(1):109-117.
3. Hasegawa T, Matsukura T, Mizuno Y, Suga Y, Ogawa H, Ikeda S. Clinical trial of a laser device called fractional photothermolysis system for acne scars. *J Dermatol*. 2006;33(9):623-627.
4. Gonzalez MJ, Sturgill WH, Ross EV, Uebelhoefer NS. Treatment of acne scars using the plasma skin regeneration (PSR) system. *Lasers Surg Med*. 2008;40(2):124-127.

5. Munavalli GS, Smith S, Maslowski JM, Weiss RA. Successful treatment of depressed, distensible acne scars using autologous fibroblasts: a multi-site, prospective, double blind, placebo-controlled clinical trial. *Dermatol Surg.* 2013;39(8):1226-1236.
6. Fabbrocini G, Fardella N, Monfrecola A, Proietti I, Innocenzi D. Acne scarring treatment using skin needling. *Clin Exp Dermatol.* 2009;34(8):874-879.
7. Gawdat HI, Hegazy RA, Fawzy MM, Fathy M. Autologous platelet rich plasma: topical versus intradermal after fractional ablative carbon dioxide laser treatment of atrophic acne scars. *Dermatol Surg.* 2014;40(2):152-161.
8. Cho SI, Chung BY, Choi MG, et al. Evaluation of the clinical efficacy of fractional radiofrequency microneedle treatment in acne scars and large facial pores. *Dermatol Surg.* 2012;38(7, pt 1):1017-1024.
9. Ross V, Naseef G, Lin G, et al. Comparison of responses of tattoos to picosecond and nanosecond Q-switched neodymium:YAG lasers. *Arch Dermatol.* 1998;134(2):167-171.
10. Brauer JA, Reddy KK, Anolik R, et al. Successful and rapid treatment of blue and green tattoo pigment with a novel picosecond laser. *Arch Dermatol.* 2012;148(7):820-823.
11. Saedi N, Metelitsa A, Petrelli K, Arndt KA, Dover JS. Treatment of tattoos with a picosecond alexandrite laser: a prospective trial. *Arch Dermatol.* 2012;148(12):1360-1363.
12. Woo SH, Park JH, Kye YC. Resurfacing of different types of facial acne scar with short-pulsed, variable-pulsed, and dual-mode Er:YAG laser. *Dermatol Surg.* 2004;30(4, pt 1):488-493.
13. Karnik J, Baumann L, Bruce S, et al. A double-blind, randomized, multicenter, controlled trial of suspended polymethylmethacrylate microspheres for the correction of atrophic facial acne scars. *J Am Acad Dermatol.* 2014;71(1):77-83.
14. Sardana K, Manjhi M, Garg VK, Sagar V. Which type of atrophic acne scar (ice-pick, boxcar, or rolling) responds to nonablative fractional laser therapy? *Dermatol Surg.* 2014;40(3):288-300.
15. Rao J. Treatment of acne scarring. *Facial Plast Surg Clin North Am.* 2011;19(2):275-291.
16. Dreno B, Khammari A, Orain N, et al. ECCA grading scale: an original validated acne scar grading scale for clinical practice in dermatology. *Dermatology.* 2007;214(1):46-51.
17. Goodman GJ, Baron JA. Postacne scarring: a quantitative global scarring grading system. *J Cosmet Dermatol.* 2006;5(1):48-52.
18. Goodman GJ, Baron JA. Postacne scarring: a qualitative global scarring grading system. *Dermatol Surg.* 2006;32(12):1458-1466.
19. Friedman PM, Skover GR, Payonk G, Kauvar AN, Geronemus RG. 3D in-vivo optical skin imaging for topographical quantitative assessment of non-ablative laser technology. *Dermatol Surg.* 2002;28(3):199-204.
20. Weiss ET, Chapas A, Brightman L, et al. Successful treatment of atrophic postoperative and traumatic scarring with carbon dioxide ablative fractional resurfacing: quantitative volumetric scar improvement. *Arch Dermatol.* 2010;146(2):133-140.
21. Xu XG, Luo YJ, Wu Y, et al. Immunohistological evaluation of skin responses after treatment using a fractional ultrapulse carbon dioxide laser on back skin. *Dermatol Surg.* 2011;37(8):1141-1149.
22. Yoo KH, Ahn JY, Kim JY, Li K, Seo SJ, Hong CK. The use of 1540 nm fractional photothermolysis for the treatment of acne scars in Asian skin: a pilot study. *Photodermatol Photoimmunol Photomed.* 2009;25(3):138-142.